



NEET-PG

PART-C

VOLUME-V
GYNAECOLOGY
& OBSTETRICS



GYNAECOLOGY & OBSTETRICS

1. Germ Cell Differentiation	1-35
2. Physiological Changes During Pregnancy	36-60
3. PIH	61-71
4. PPH	72-88
5. Molar Pregnancy	89-90
6. Pelvis	91-97
7. Steps of Normal Labour	98-106
8. Breech	107-115
9. Cesarean Section	116-119
10. Ectopic Pregnancy	120-127
11. Abortion	128-136
12. Endometrial	137-139
13. Anatomy of Cervix	140-142

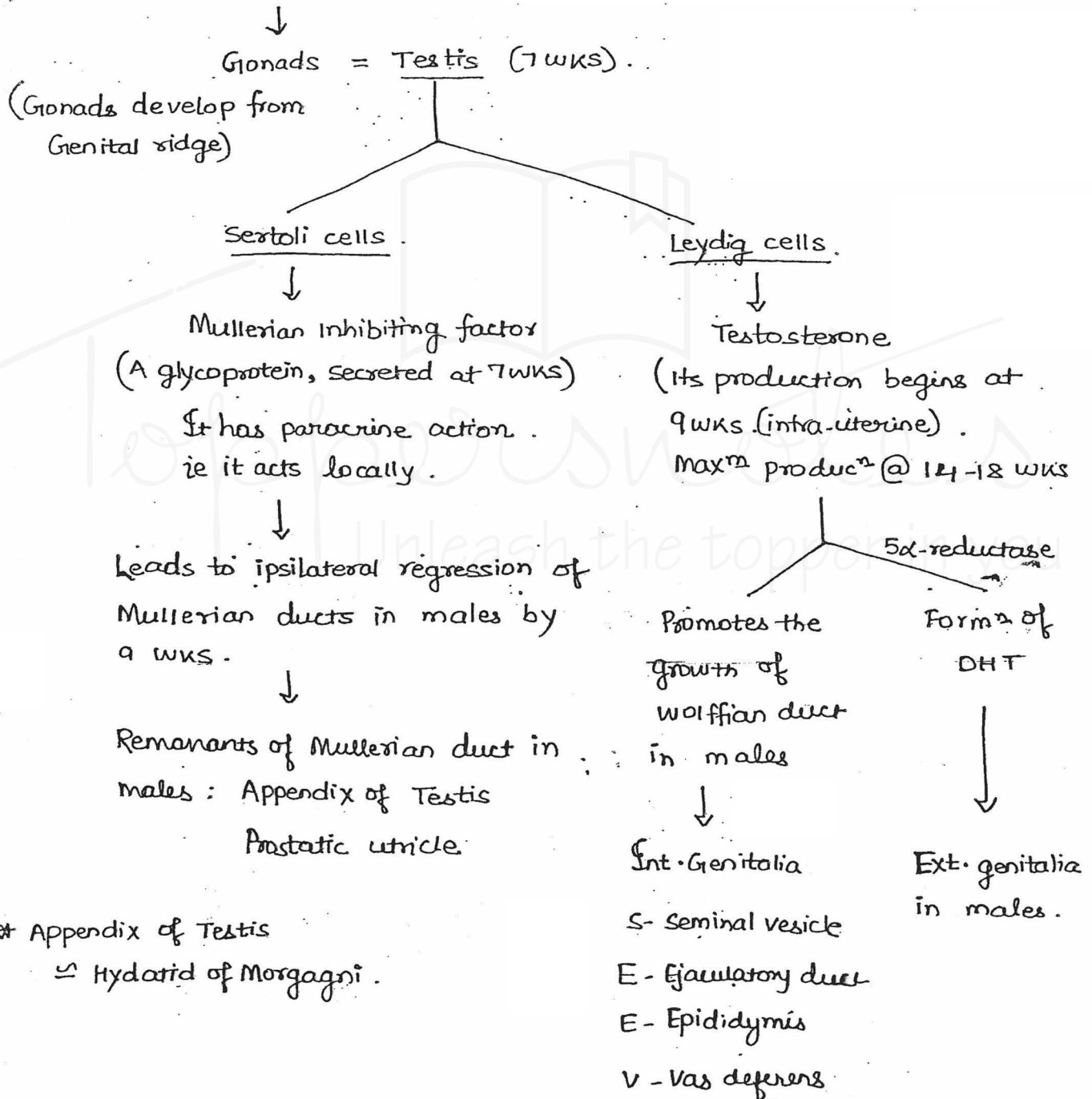
14. HPV	143-150
15. Amenorrhea	151-169
16. Infertility	170-177
17. Contraception	178-186
18. Ovarian Cyst & Pregnancy	187-188
19. Twin Pregnancy	189-191
20. Miscellaneous	192-254

Germ cell differentiation:

What determines sex in fetus : SRY gene on short arm, chromosome Y.

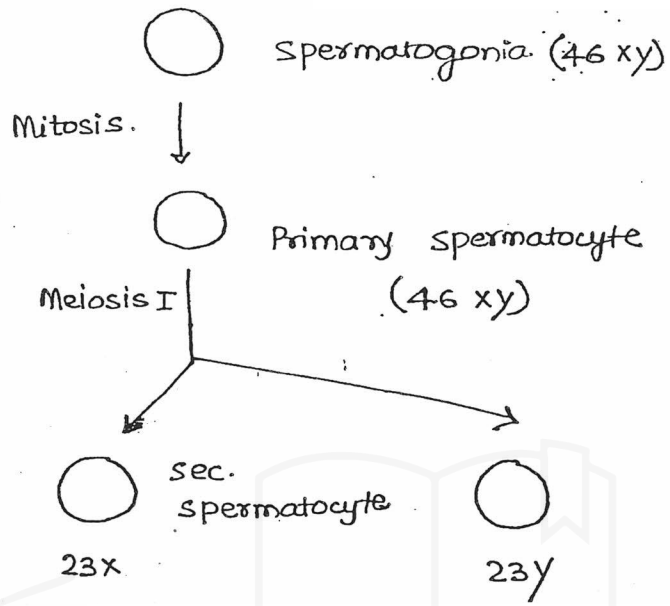
Others :

If SRY gene is present.



* Appendix of Testis
≅ Hydatid of Morgagni.

Spermatogenesis.



Toppernotes
Unleash the topper in you

Imp. points on spermatogenesis :

Begins at puberty .

Time taken : 72-75 days .

one spermatogonia forms - 16 primary spermatocyte .

one spermatocyte gives rise to 4 sperms/ spermatids .

one spermatogonia gives rise to 64 sperms/ spermatids .

Spermiogenesis :-

Spermatids change to sperms

No mitosis/ No meiosis

Time taken : 14 days .

Part of spermatid .

Part in sperm .

Nuclear material

—

Head of sperm .

Golgi body

—

Acrosomal cap .

Mitochondria

—

Middle piece .

Microtubules

—

Tail/axial filament .

* sperms lack ER (especially RER). —

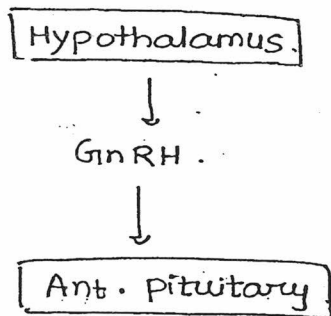
Sperms

55 μ m .

Life span - 72 hrs .

sperms attain motility & maturity in - Cranial end of epididymis .

Hormonal support of spermatogenesis :



* 1st stimulus for Leydig cells to produce testosterone: HCG.

Sperm pathway -

spermatogenesis occur @ seminiferous tubules of Testis.
(Sertoli cells)



Motility & maturity @ Epididymis (cranial end).



Vas deferens.



They are released along with seminal vesicle fluid. (60% vol^m + Fructose).

+ Prostatic fluid.

+ Bulbourethral gland secretion.



The semen which is released should liquify in 20-30 minutes.

(Liquifacⁿ d/t : prostatic fluid)

Ideally semen analysis is done on liquified semen.

But if no liquificⁿ occurs in 60 min : semen analysis on unliquified semen.

Note : If there is azoospermia with low semen volume & absent fructose → Block is below the level of seminal vesicle.

Men w/ congenital absence of vas def., suffer w/ seminal vesicle agenesi
(CAVD)

∴ They have low semen volume, low pH & low fructose.

Spermatogenesis is, however, normal.

* Absence of spermatozoa } in semen.
But presence of Fructose }

Likely diagnosis may be : Mumps orchitis.

Capacitation :

- Ability of sperms to fertilize ova
- Begins in female reproductive tract (cervix).
- Major part occurs in Fallopian tube.
- Time taken: 7 hours
- After capacitation, sperms become hyper-motile.

Acrosomal rxn :

- occurs after the sperm binds to zona pellucida
- Zona pellucida has sperm receptors: ZP₁, ZP₂ & ZP₃, which mediate acrosomal rxn (main: ZP₃).
- Acrosomal rxn occurs because enzymes like hyaluronidase, acrosin, etc. are released.

In females

SRY gene ~~into~~ Absent



Gonads = ovary.

- Whether ovary is Present/absent depends on Y chromosome.
- For dev. of ovary 2X chromosomes are needed.

Sertoli cells absent



∴ Mullerian I.F. absent



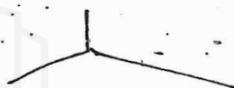
∴ Mullerian duct grows into

- Fallopian tube
- uterus
- Cervix
- upper $\frac{3}{5}$ th Vagina.

Leydig cells absent



Testosterone absent



Wolffian duct
regresses
~~is~~

Ext. genitalia
looks like
female.

∴ Lower part of vagina develops from urogenital sinus (sino-vaginal bulb)

Most common cause of ambiguous female genitalia: Presence of testosterone in intra-uterine life [congenital adrenal hyperplasia]

Remnants of Wolffian ducts in females :-

<u>Part of Wolffian duct</u>	<u>Remnants in females</u>
1. Pronephros - - forms -	Hydatid of Morgagni / Kobelt tubercle.
2. Mesonephros .	
• Cranial end. _____	Epo-oophoron / organ of Rosenmüller
• Caudal end. _____	Para-oophoron.
3. Wolffian duct proper _____	Gartner's duct.

All remnants of Wolffian duct is present in lateral part of broad ligament, except para-oophoron, which is present in medial part of broad ligament.

- * Wolffian duct \cong Mesonephric duct
- * Mullerian duct \cong Para-mesonephric duct.

* Organ of Rosenmuller :

- consists vertical tubules. (Not Horizontal tubules)
- Lined by cuboid epithelia (Not by columnar epithelia).

Oogenesis.

(46
XX)

oogonia



MITOSIS.

(46
XX)

- Primary oocyte.



MEIOSIS I : arrested in Diplotene (Prophase)

* This arrested stage is known as

: Dictyate stage . (upto puberty).

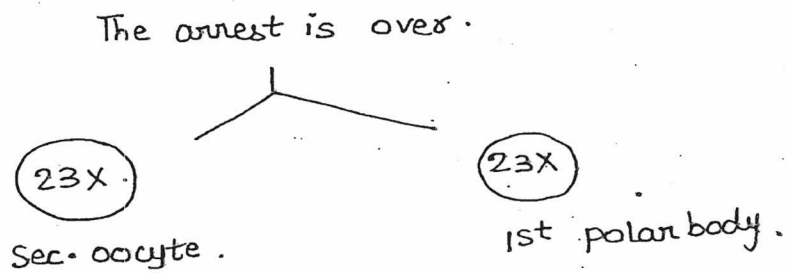
↳ This stage is absent in spermatogenesis.

At puberty, Meiosis I is resumed.

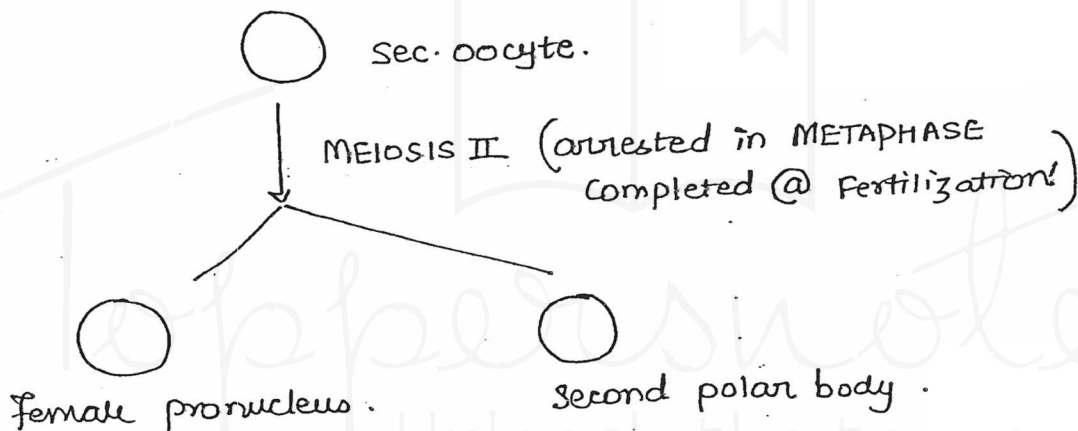
Meiosis is hormone dependent. \rightarrow LH

\therefore Meiosis I is resumed 24-36 hours before ovulation.


At puberty :



Release of sec. oocyte from primary is w/a ovulation.



- size of ova : 120 microns (largest cell of body).



PRIMORDIAL follicle . (size : 0.02 mm)

* size of follicle just before ovulⁿ = 18-20/mm

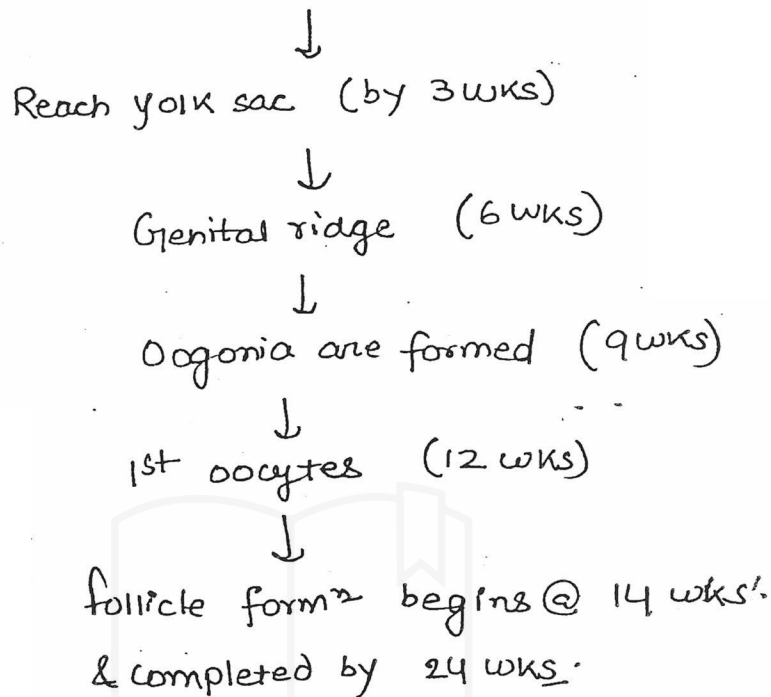
* Max^m no. of follicles @ 20 wks (5th month of intra-uterine life)
- 6-7 millions.

At birth : 1-2 millions

At Puberty : 4-5 lakhs.

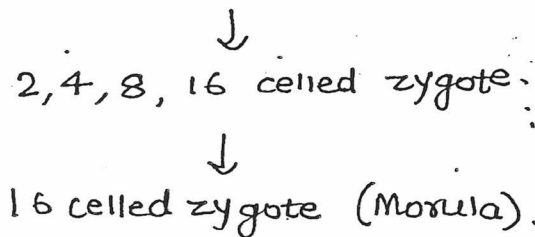
400-500 follicles mature in entire lifetime.

Germ cells are derived from Epiplast/ectoderm.



- Fertilization:

- site : ampulla (FT)
- zygote undergoes cell division.



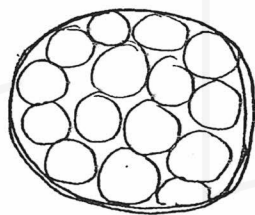
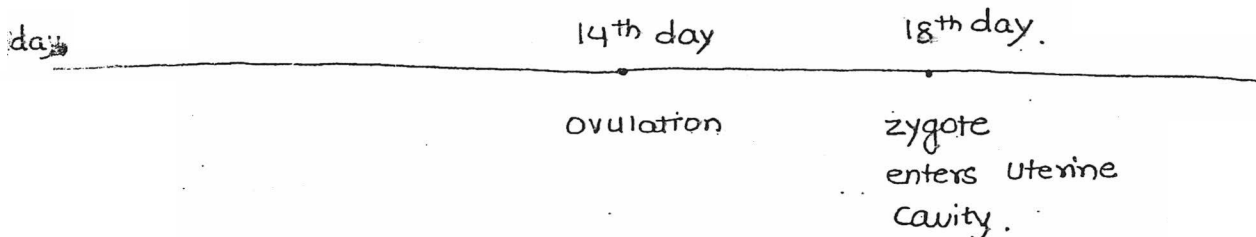
* zygote stays in Fallopian tube for 3 days.

Then it moves towards uterine cavity d/t:-

- (i) peristalsis of tube
- (ii) Movement of cilia

Nutrition to the zygote in F.T. is provided by secretory cells of FT. in the form of pyruvate.

* zygote enters the uterine cavity : Day 4 after fertilizⁿ!!



Morula

— zona pellucida

(on 5th day zona pellucida is lost & this is k/a Zona Hatching).

As the Morula enters uterine cavity, fluid enters into it. & Now it is k/a BLASTOCYST.

In Blastocyst, cells are arranged in 2 manners.

↳ ~~Some~~ TROPHOBLAST : which lines the Blastocyst.

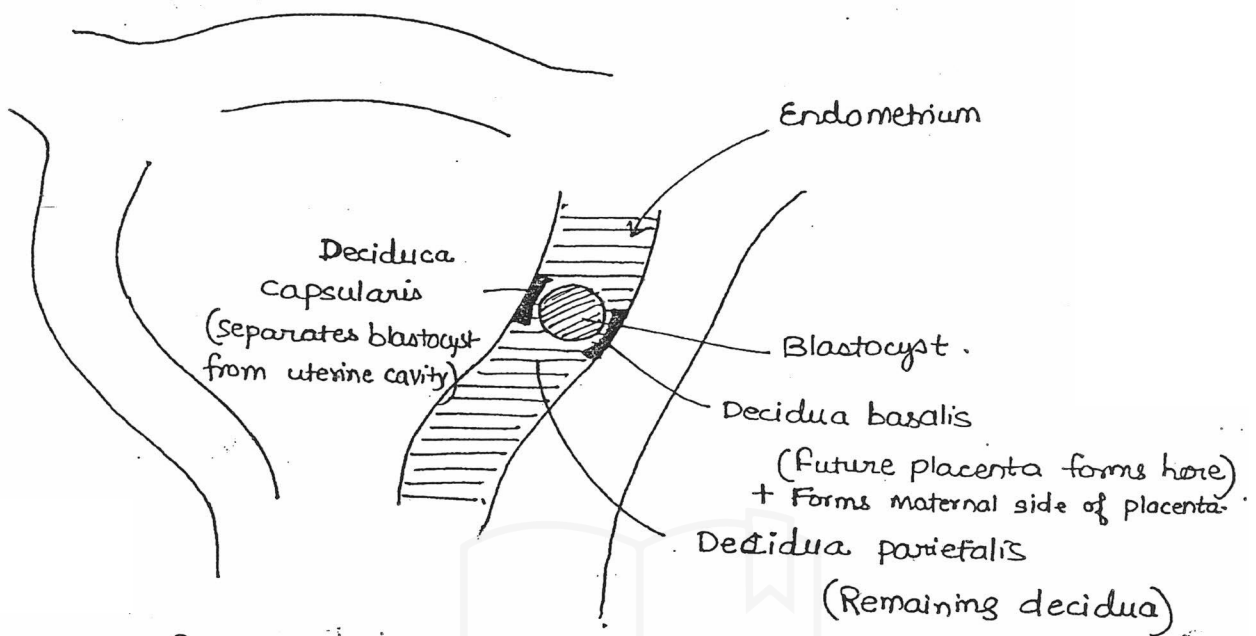
↳ Inner cell mass :

Implantation :

occurs in the form of Blastocyst

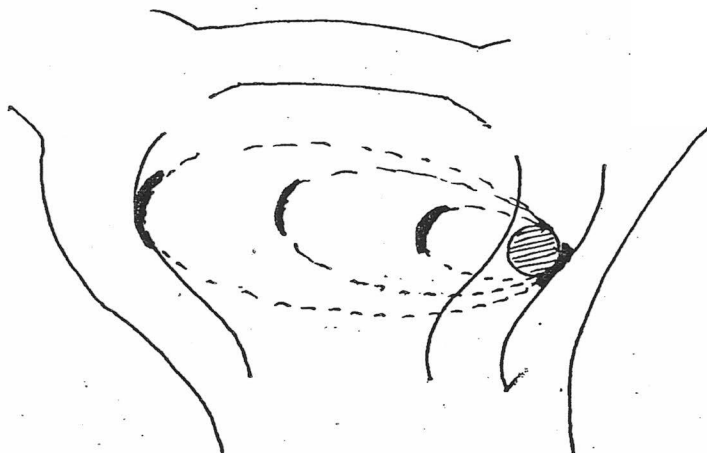
6-7 ~~days~~ days after fertilization : Beginning.

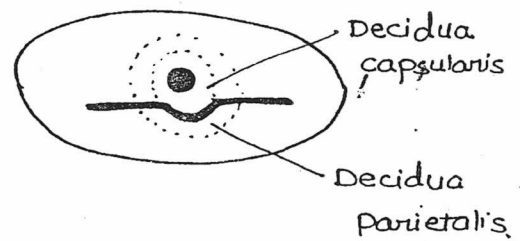
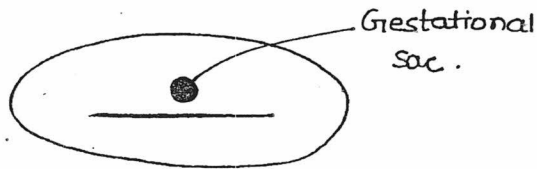
Completed by 10 days after fertilization



• Interstitial implantation.

- Thickness of endometrium at time of implantation = 8mm
- In some females, bleeding occurs at the time of implantation
 - HARTMAN'S sign.
- After implantation, Endometrium is k/a Decidua.
- As the fetus grow, Decidua basalis & decidua parietalis fuse by 16 wks. (uterine cavity obliteration).
- ∴ superfetation could be possible only before uterine cavity obliteration i.e. by 16 wks.



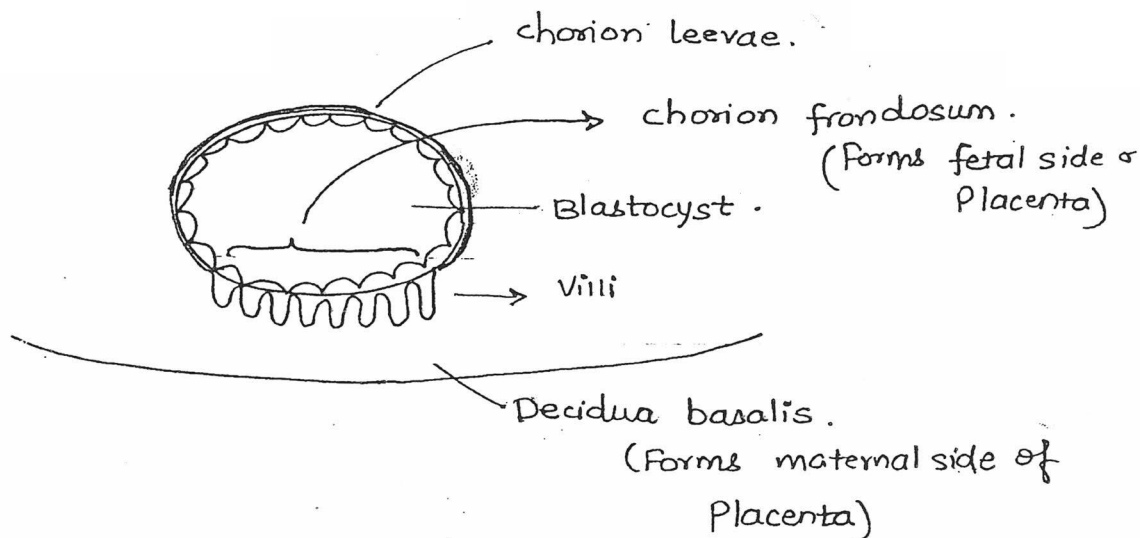


- Double ring sign-
(at

~~Double ring sign is absent in Ectopic Pregnancy :-~~

- Embryonic period : 3-8 wks after fertilization.
(5-10 wks after pregnancy).
↳ Most teratogenic period.
- Fetal period : From 9 wks after fertilization upto delivery.
- First germ layer formed in fetus : Endoderm.

Trophoblast $\left\{ \begin{array}{l} \text{Cyto-trophoblast} \\ \text{Syncytio-trophoblast} \end{array} \right. \left| \begin{array}{l} \text{This differentiation occurs} \\ \text{8th day after fertilis}^n \end{array} \right.$



• Fetal membranes.

Amnion.

- Formed @ Day 10, 11. - after fertilisn.
- Derived from ectoderm
- Innermost fetal memb.
- Avascular; provides tensile strength to fetal memb.

Chorion.

Formed 8 days after fertilisn

Chorion leevae: Fuses to amnion.

Chorion frondosum

Yolk sac.

First site for hematopoiesis

Allantois.

- A diverticula that arises from hindgut & grows into connecting stalk.

† Prostaglandin predominantly present in fetal memb. - PGI_2
 ∴ when fetal memb. are ruptured during labour →
 Prostaglandins are released. & labour proceeds @ faster rate

Site of hematopoiesis

- | | | |
|--------------------------------|----------------|-------------------------|
| 1. yolk sac. | 3-6 wks. | Gower 1, 2
Portland. |
| 2. Liver (mainly)
& spleen. | \geq 6 wks. | HbF |
| 3. Bone marrow | \geq 20 wks. | HbA. |

Fetal RBCs have larger size.
but short life span. (90 days)

Fetal Hb. at term = 18 gm%. (75-80% is HbF).

Switch over of fetal Hb. to Adult Hb. begins at 36 wks & is completed by 6 months after birth. (HbF < 1% @ 6 months)

This shift is carried by Gluco-corticoids.

HbF

HbA.

- Less of 2,3DPG.
- \therefore Higher affinity for O_2 .

- Less of carbonic anhydrase
- Resistant to acid & alkali

- ~~More~~ 2,3DPG.
- \therefore Less affinity for O_2

- More.
- Sensitive to acid & alkali
- \therefore gets hemolysed.

* Apt test / singer alkali denaturation test.

- It is a qualitative test done in vasa previa, to differentiate b/w maternal & fetal blood.